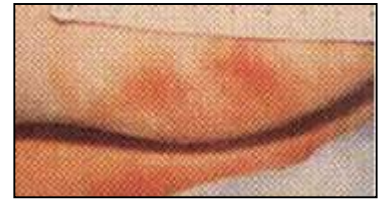
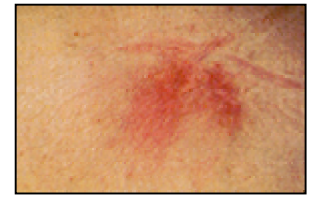

# Pressure Ulcer Staging

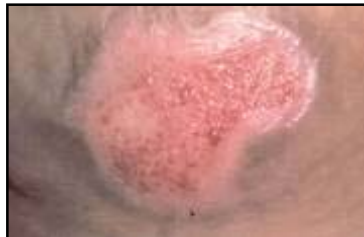
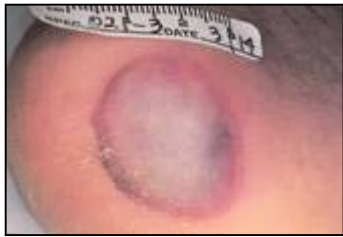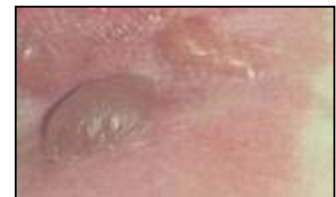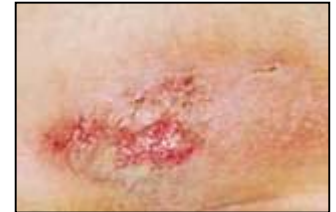## Stage I:

An observable pressure related alteration of intact skin whose indicators as compared to the adjacent or opposite area on the body may include changes in one or more of the following: skin temperature (warmth or coolness), tissue consistency (firm or boggy feel) and/or sensation (pain, itching). The ulcer appears as a defined area of persistent redness in lightly pigmented skin, whereas in darker skin tones, the ulcer may appear with persistent red, blue, or purple hues.



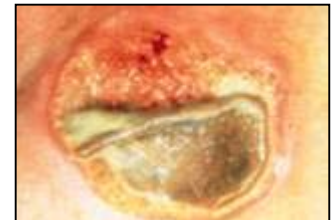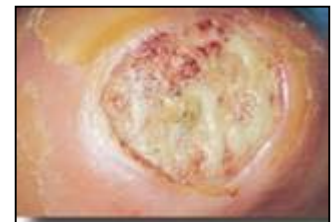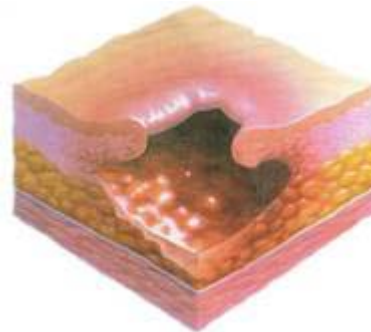
## Stage II:

Partial thickness skin loss involving epidermis, dermis, or both. The ulcer is superficial and presents clinically as an abrasion, blister or shallow crater.



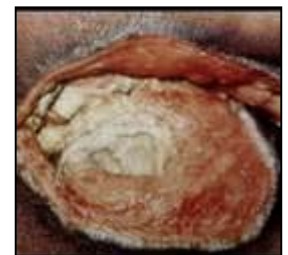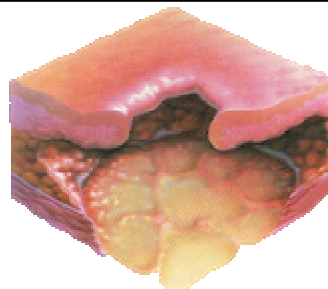## Stage III:

Full thickness skin loss involving damage to, or necrosis of, subcutaneous tissue that may extend down to, but not through, underlying fascia. The ulcer presents clinically as a deep crater with or without undermining of adjacent tissue.



## Stage IV:

Full thickness skin loss with extensive destruction, tissue necrosis, or damage to muscle, bone, or supporting structures (e.g. tendon, joint capsule). Undermining and sinus tracts also may be associated with Stage IV pressure ulcers.



## Eschar

Thick dry black necrotic tissue — Unstageable

